

## Observational Report

## Pelvic Neuralgias by Neuro-Vascular Entrapment: Anatomical Findings in a Series of 97 Consecutive Patients Treated by Laparoscopic Nerve Decompression

Marc Possover MD, PhD<sup>1,2</sup>, and Axel Forman MD, PhD<sup>2</sup>

From: <sup>1</sup>Possover International Medical Center, Zürich, Switzerland; <sup>2</sup>Department for Gynecology and Neuropelvelogy, University of Aarhus, Aarhus, Denmark

Address Correspondence: Marc Possover, PhD, MD Possover International Medical Center Witellikerstrasse 40, CH- 8032 Zürich E-mail: m.possover@possover.com

Disclaimer: There was no external funding in the preparation of this manuscript.

Conflict of interest: Each author certifies that he or she, or a member of his or her immediate family, has no commercial association (i.e., consultancies, stock ownership, equity interest, patent/licensing arrangements, etc.) that might pose a conflict of interest in connection with the submitted manuscript.

Manuscript received: 01-28-2015  
Revised manuscript received: 05-25-2015  
Accepted for publication: 05-28-2015

Free full manuscript: [www.painphysicianjournal.com](http://www.painphysicianjournal.com)

**Background:** Some patients have pelvic, pudendal, or low lumbar pain radiating into the legs that is worse while sitting but differs from pudendal neuralgia. The purpose of this study was to present a new clinical entity of neuropathic pelvic pain by pelvic neuro-vascular entrapment.

**Objectives:** To report about the locations of predilection for pelvic neurovascular entrapment.

**Study Design:** Prospective cohort pre- and post-intervention.

**Setting:** University referral unit specializing in advanced gynecological surgery and neuropelvelogy.

**Methods:** Patients, Intervention: In a prospective study, 97 patients presenting with intractable pelvic neuropathic pain (pudendal pain, gluteal pain, vulvodynia, coccygodynia, and sciatic pain) underwent laparoscopic exploration with decompression of compressed pelvic somatic nerves. The population included 76 (78.3%) women and 21 men. Indication for laparoscopic exploration of pelvic nerves suspected to be involved in pain has been indicated after neuropelvelogical work up, pelvic neuro-magnetic resonance imaging (MRI) and Doppler-sonography. Pain evolution was recorded over 2 years after the procedure.

**Measurements and Main Results:** Three entities were isolated: pudendal neuralgie by compression at the less sciatic notch, sacral radiculopathy at S2-4 by compression at the infracardinal level of the sacral plexus, and sciatica L5-S1/2 by compression at the greater sciatic notch. Pain was worse sitting (98%), during menstrual bleeding in women, and during Valsalva maneuver, but the pain did not wake the patients up at night and was not accompanied by neurologic dysfunctions. A decrease in VAS scores (> 50%) at 2 years follow-up was observed in 86 patients (88.6%).

**Conclusions:** Neuro-vascular entrapment is a pathophysiologic phenomenon implicated in several pelvic neuropathies. The most common are L5-S1 sciatica, pudendal neuralgia, and sacral radiculopathy. After intraoperative confirmation, laparoscopic exploration of the entire sacral plexus is essential to diagnose conflict. Laparoscopic decompression is a treatment of choice, based on the separation of the offending vessel from the nerves. Those procedures are safe, with a high success rate; the neuropelvelogical approach is essential in order to obtain good treatment results. The laparoscopic approach gives the possibility of reducing morbidity and improving results by providing wider insight into the operating field with smaller intraoperative injury.

**Key words:** Vulvodynia, coccygodynia, chronic pelvic pain, pudendal pain, neuro-vascular conflict

**Pain Physician 2015; 18:E1139-E1143**

Low lumbar pain radiating into the buttock and the leg without focal neurologic deficit has a high prevalence in the general population. Classical diagnostic workup focuses on pathologies

of the spinal cord and of vertebral column. When no causes are discovered, treatment is all too often limited to medical treatments, infiltrations, and physiotherapy for pain control. Pathologies of the

pelvic nerves, especially the sacral plexus are then by and large simply ignored. The same phenomenon of omission of pelvic nerves pathologies is observed for pain conditions such as vulvodynia, coccygodynia, or incomplete pudendal pain: When no morphologic correlate is found, prescriptions of pain killers, local topics, or psychiatric medications build the classical treatment. The only really investigated pelvic nerve pathology is the pudendal neuralgia by compression of the nerve at the Alcock's canal – the Alcock's canal syndrome. The popularity of this condition is obviously due to the fact that this nerve is accessible from below for neurophysiological exploration, infiltrations, and surgical decompression. In contrast, pathologies of intrapelvic nerves are difficult to access and have been less investigated. The sacral and lumbal plexuses are currently lumped together in the literature as the "lumbosacral plexus," despite the fact that both plexuses are anatomically and functionally totally different. The feasibility of a surgical approach and a functional exploration of the endopelvic nerves by laparoscopy has significantly increased the awareness that pelvic nerve pathologies may exist and may be responsible for a lot of intractable chronic pelvic pain conditions (1). One etiology recently becoming a focus of interest for explanation of intractable neuropathic pelvic pain is the so called "pelvic neuro-vascular conflict" as a result of the vulnerability of nerves as they pass in close relationship with enlarged pelvic vessels (2-6). We reported previously on our clinical experience with the laparoscopic decompression of pelvic nerves from such pelvic neurovascular entrapment (7). In the present manuscript, we report on our anatomic findings in a series of 97 consecutive patients who underwent laparoscopic treatment for pelvic neurovascular entrapment.

## **METHODS**

We report here on consecutive patients presented in our department since 2006 for treatment for intractable neuropathic pelvic pain in whom laparoscopy confirmed a pelvic neuro-vascular conflict. All patients affected by any neurogenic conditions (e.g., stroke, multiple sclerosis, spinal cord injury), pelvic neuropathies (such as Alcock's canal syndrome, surgical damages, endometriosis, pelvic tumor), or pelvic disorders after chemotherapies/radiotherapies were excluded from the study. All patients underwent a preoperative neuropelvic work up with particular attention paid to pelvic congestion syndrome, pelvic enlarged

veins, but also for exclusion of any neurogenic etiology (e.g., schwannoma, myelomeningocele) (8).

The surgical procedure consists of the exploration of the pelvic nerves of interest, confirmation of a neuro-vascular conflict, as well as the separation of the vessels from the nerves followed by coagulation/transsection of the vessels. Based on intraoperative findings, we elaborated prospectively a cartography of locations of predilections for pelvic neuromuscular conflict to the different area of the sacral plexus (Fig. 1).

All surgical data, pain evolutions, complications, and intraoperative findings were collected prospectively in an Excel database. This series was designed as a prospective cohort study pre-and post-intervention since surgeries were always considered by the patients and the physicians as the last therapeutic option, especially after failure of or unacceptable side effects form medical treatments. All patients in this study refused inclusion in a randomized clinical trial. Every patient provided written informed consent for the procedure and for data collection.

## **RESULTS**

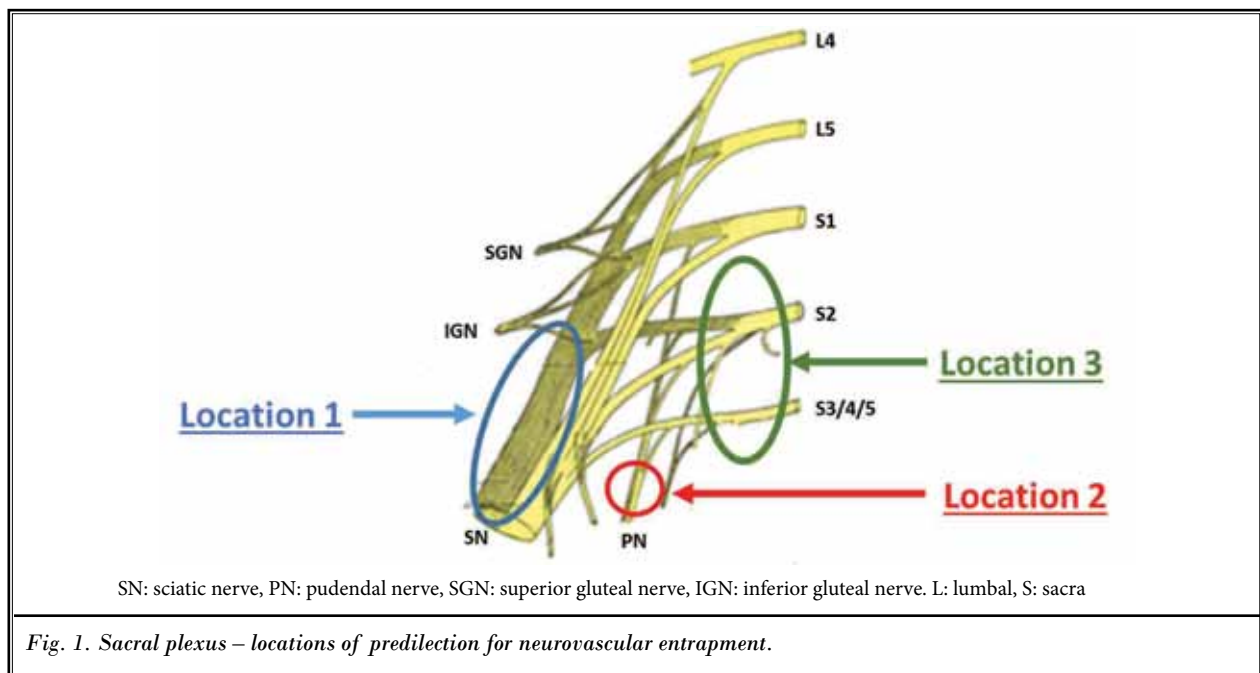
Ninety-seven consecutive patients were included in this study, 76 women and 21 men. Mean age of patients was 52 years (29 – 93) and mean body mass index (BMI) 30.4 (21 – 34).

All procedures were performed by laparoscopy without any conversion to laparotomy and no major intra- or post-operative complications occurred. Mean surgical time was 67 minutes (34 – 190 minutes).

Three locations of predilection for pelvic neuro-vascular conflict were identified (Fig. 1).

### **Location 1**

Compression of the distal portion of the lumbosacral trunk between the linea terminalis and enlarged varicose veins, and/or the sciatic nerve just before it entry through the great sciatic notch (n = 11). All these patients suffer from non-neurogenic L5/S1-sciatica; only 36% from a S2 complained of sciatica with some pain in pudendal areas (mostly perianal/perinal pain). Laparoscopic exploration showed enlarged varicose veins located in the lumbosacral space, anastomosing with the internal iliac veins, the gluteal veins, or the obturator vein. In 12 patients, we found an atypical superior gluteal vein crossing over the sciatic nerve and compressing the superior gluteal nerve. In 3 patients, we found an enlarged inferior gluteal vein pressing the nerve to the great sciatic notch. Treatment consisted of separa-



tion of the vessels from the nerves and coagulation/ transection of them.

### Location 2

Compression of the pudendal nerve at the less sciatic notch (n = 24). All patients presented with pudendal pain in all 3 areas (ventral, middle, and dorsal pudendal areas) without sciatic pain. Forty-two percent of the patients also suffered from a therapy-refractory hypersensitivity of the bladder, while 12% suffered from overactive bladder. Laparoscopic exploration showed a compression of the pudendal nerve between the sacrospinous ligament and 2 enlarged pudendal veins. Treatment consisted of transection of the ligament, and if feasible, transection of the veins.

### Location 3

Compression of the sacral nerves root S2,3,4 after their emergence out of the sacral foramen, between laterally the piriform muscle and medially the sacral hypogastric fascia (n = 62). Patients presented with neuropathic pains such as vulvodynia, coccygodynia, or partial pudendal pain (anterior, middle, or dorsal pudendal pain), 15% presented with S2-sciatica. All of them reported pollakisuria (micturition > 8 per day), only 17% nycturia. Laparoscopic exploration showed massive dilated sacral veins in all patients compressing or even entrapping the nerves. In 3 patients, we found fibers of the piriformis muscle with medial insertion entrapping

the sacral nerves S2 or S3. Treatment consisted in transection of the pararectal hypogastric fascia with dissection/transection of the veins and in the 3 mentioned patients, transection of part of the piriformis muscle.

We had loss to follow-up in 3 patients. The mean reduction in Visual Analog Score (VAS) at 24 months of at least 50% of preoperative VAS-score was obtained in 88.6% of the patients (n = 86). Most patients reported a period of "post-decompression syndrome" occurring after a few days of postoperative pain relief, characterized by the reappearance of severe allodynia with cutaneous paresthesia. Decreasing pain began in more than 95% of the patients after a postoperative period of 4 – 6 months.

### DISCUSSION

Pelvic pain, acute or chronic, is a common complaint in daily medical practice. Numerous pelvic pathologies responsible for pelvic pain have been reported in the literature. Pelvic pain can be classified into visceral and somatic pain. Somatic pains are mostly correlated to an involvement of the sacral plexus and its branches. Some of these etiologies, such as surgical damages and endometriosis of the pelvic nerves, were considered as extremely uncommon in the past, but are increasing in popularity. However, laparoscopic topographic, and functional exploration of the pelvic nerves showed us some analogy to a condition well known by neurosurgeons, called "neuro-vascular con-

flict" as a pain etiology. This condition correspond to a nerve irritation (non-neurogenic condition) as a result of the vulnerability of the nerve as it passes in close relationship with vessels. However, dilated veins alone, even close to nerves, do not induce neuropathic pain. Pain occurs only if the nerves are truly entrapped between 2 or more vessels, or between a fixed anatomical structure (ligament, bone, fascia, muscle) and vessels, or by one or more vessels in a confined anatomical space. In the location 1, pain occurred by compression of the lumbosacral trunk and/or the sciatic nerve between enlarged veins and the iliac bone (linea terminalis). In location 2, the nerves were entrapped by enlarged vein(s) in the lesser sciatic notch, and in location 3 by enlarged veins in the confined space between the piriformis muscle and the sacral hypogastric fascia. All situations that increase venous blood flow (such as sitting, prolonged standing, tricuspid insufficiency) result in an increased irritation of the nerves with deterioration of the pain situation. In contrast, situations of life that decrease the venous blood pressure (e.g., lying, sleeping, hypotonic treatment) improve the painful situation. Because pelvic and leg veins are at risk for venous insufficiency by damaged valves, patients with varicosities in the legs are at risk for pelvic varicose veins. Also, pelvic interventions and thrombosis may promote changes in pelvic veins circulation; since simple tubal sterilization may induce uterine congestion and pelvic venous stasis (9), there is no doubt that interventions such as hysterectomies or prostatectomies may also induce development of pelvic varicose veins.

Different treatments for pelvic congestion syndrome have been reported in the literature (including

transvenous catheter embolization and surgical ligation) but current treatment studies reporting ordinal outcomes found improvement from 24% to 100% (10). Surgical treatment based on ligation of the ovarian veins have not shown significant long-term efficacy (11), and available evidence is also not sufficient to determine whether embolization is effective (12-20). Because a venous stasis upstream after embolization might induce formation of collateral veins responsible for recurrence, the laparoscopic resection of sacral varicose veins at the location of the neurovascular entrapment might be a more selective and adaptive treatment.

## CONCLUSION

In consideration of the tragic situation of patients suffering from intractable neuropathic pelvic pains and the amount of inadequate, ineffective but also invasive treatments that are still proposed to these patients (7), pelvic neuro-vascular conflicts must be considered as a potential etiology in such conditions. Not only might the Alock's canal syndrome induce pain while sitting, but pelvic neuromuscular conflicts especially to the sacral nerves root S2, S3 and S4 too.

The most important step in diagnostic workup is the recognition of the neuropathic non-neurogenic and pelvic origin of the symptoms. Laparoscopic exploration of the nerves suspected of being compressed is then the key for a proper diagnosis and adapted treatment. These procedures are safe, with a high rate success; nevertheless, the results are directly correlated with the quality of the preoperative neuropelvic diagnosis.

## REFERENCES

1. Possover M. New surgical evolutions in management of sacral radiculopathies. *Surg Technol Int* 2010; 19:123-128.
2. Grgi V. Piriformis muscle syndrome: etiology, pathogenesis, clinical manifestations, diagnosis, differential diagnosis and therapy. *Lijec Vjesn* 2013; 135:33-40.
3. Hu MH, Wu KW, Jian YM, Wang CT, Wu IH, Yang SH. Vascular compression syndrome of sciatic nerve caused by gluteal varicosities. *Ann Vasc Surg* 2010; 24:1134.
4. Ramírez García S, Gutiérrez Salinas J, Núñez Ramos NR, Maldonado Velázquez AJ, Hernández Rodríguez S, Carranza Castro H, García Ortiz L. May-Thurner syndrome as a cause of neurovascular compression of the pudendal nerve. *Ginecol Obstet Mex* 2013; 81:105-108.
5. Possover M, Schneider T, Henle KP. Laparoscopic therapy of endometriosis and vascular entrapment of sacral plexus. *Fert Steril* 2011; 95:756-758.
6. Zhong H, Gan J, Zhao Y, Xu Z, Liu C, Shao G, Wu X. Role of CT Angiography in the diagnosis and treatment of popliteal vascular entrapment syndrome. *AJR Am J Roentgenol* 2011; 197:W1147-W1154.
7. Possover M. Sacral radiculopathies by "Pelvic Compartment Syndrome" – a unknown cause for unexplained intractable neuropathic chronic pelvic pain. *Ref Gynecol Obstet* 2014; 16:1-3.
8. Possover M, Forman A. Neuropelvic assessment of neuropathic pelvic pains. *Gyneco Surg* 2014; 11:139-144.
9. El-Minawi MF, Mashhor N, Reda MS. Pelvic venous changes after tubal sterilization. *J Reprod Med* 1983; 28:641-648.
10. Tu FF, Hahn D, Steege JF. Pelvic congestion syndrome-associated pelvic pain: A systematic review of diagnosis and management. *Obstet Gynecol Surv* 2010; 65:332-340.
11. Gargiulo T, Mais V, Brokaj L, Cosu E, Melis GB. Bilateral laparoscopic transperitoneal ligation of ovarian

- veins for treatment of pelvic congestion syndrome. *J Am Assoc Gynecol Laparosc* 2003; 10:501-504.
12. Maleux G, Stockx L, Wilms G, Marchal G. Ovarian vein embolization for the treatment of pelvic congestion syndrome: Long-term technical and clinical results. *J Vasc Interv Radiol* 2000; 11:859-864.
  13. Sichelau MJ, Yao JS, Vogelzang RL. Transcatheter embolotherapy for the treatment of pelvic congestion syndrome. *Obstet Gynecol* 1994; 83:892-896.
  14. Venbrux AC, Lambert DL. Embolization of the ovarian veins as a treatment for patients with chronic pelvic pain caused by pelvic venous incompetence (pelvic congestion syndrome). *Curr Opin Obstet Gynecol* 1999; 11:395-399.
  15. Tarazov PG, Prozorovskij KV, Ryzhkov VK. Pelvic pain syndrome caused by ovarian varices. Treatment by transcatheter embolization. *Acta Radiol* 1997; 38:1023-1025.
  16. Kim HS, Malhotra AD, Rowe PC, Lee JM, Venbrux AC. Embolotherapy for pelvic congestion syndrome: Long-term results. *J Vasc Interv Radiol* 2006; 17:289-297.
  17. Kwon SH, Oh JH, Ko KR, Park HC, Huh JY. Transcatheter ovarian vein embolization using coils for the treatment of pelvic congestion syndrome. *Cardiovasc Intervent Radiol* 2007; 30:655-661.
  18. Creton D, Hennequin L, Kohler F, Allaert FA. Embolisation of symptomatic pelvic veins in women presenting with non-saphenous varicose veins of pelvic origin - three-year follow-up. *Eur J Vasc Endovasc Surg* 2007; 34:112-117.
  19. Gandini R, Chiocchi M, Konda D, Pampana E, Fabiano S, Simonetti G. Transcatheter foam sclerotherapy of symptomatic female varicocele with sodium-tetradecyl-sulfate foam. *Cardiovasc Intervent Radiol* 2008; 31:778-784.
  20. Tropeano G, Di Stasi C, Amoroso S, Cina A, Scambia G. Ovarian vein incompetence: A potential cause of chronic pelvic pain in women. *Eur J Obstet Gynecol Reprod Biol* 2008; 139:215-221.

